

# Oncology: Osteosarcoma



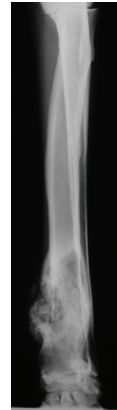San Diego  
10435 Sorrento Valley Road  
San Diego CA 92121  
858 875 7500  
www.vshsd.com

North County  
2055 Montiel Road  
San Marcos CA 92069  
760 466 060  
www.vshsd.com

## CANINE OSTEOSARCOMA

\_\_\_ *Your dog has been diagnosed with a bone lesion most likely caused by a type of bone cancer called osteosarcoma.*

An option for confirming diagnosis of this condition is ultrasound-guided fine needle aspirates of the lesion (as opposed to surgical biopsy for histologic diagnosis). This technique will provide an accurate diagnosis in 75 - 90% of patients, enabling the patient's family to feel most comfortable when moving forward with treatment decisions. However, it is reasonable to proceed with amputation based on x-ray appearance alone, based on high likelihood of osteosarcoma as the cause of the bone lesion. Prior to radiation therapy or limb spare surgery, a cytologic or histologic diagnosis is recommended.



Other causes of destructive bone lesions are infection (fungal or bacterial) and other types of cancer, though these are rare. Fungal disease of the bone is difficult to treat; we expect a favorable outcome in approximately 50% of bone fungal cases treated medically. The treatment can be ongoing for months (an oral medication that can be expensive in a large dog) and some cases ultimately require an amputation to cure the patient due to difficulty eradicating the fungal disease from the bone even with chronic, appropriate medications.


Other tumors of the bone are far less common and are associated with variable prognoses depending on tumor type; some better than osteosarcoma (fibrosarcoma), some less favorable (hemangiosarcoma).

\_\_\_ *Your dog has been diagnosed with osteosarcoma.*

Prognosis for osteosarcoma: Without treatment, most families elect euthanasia relatively soon after diagnosis due to pain that cannot be adequately controlled with medication.

### Surgery:

*Amputation:* Reported median survival following amputation alone (without chemotherapy) is 4-5 months, with 10% survival expected at one year. Following a combination of treatment with amputation and chemotherapy, median survival is close to a year with 10-20% of patients surviving to 2+ years. Ultimately, patient survival is typically limited by metastatic spread of the tumor to the lungs. With appropriate patient selection, most dogs fare very well following amputation.



*Limb spare:* The limb spare surgical procedure is an attractive treatment if amputation is not an option (such as for patients with advanced hip or stifle disease) and the tumor is located in the lower forelimb. The advantage of the limb spare procedure is a comfortable, functional limb following surgical healing, and the disadvantages are the potential for infection, implant failure, and local tumor recurrence that sometimes occur. Survival following limb spare surgery + chemotherapy is similar to amputation + chemotherapy.



### **Chemotherapy:**

In combination with the pain relief treatment option chosen, chemotherapy is generally administered as an intravenous dose of **carboplatin** administered once every 3 weeks for 4 doses, starting approximately 1 week post-surgery or in combination with radiation therapy. Carboplatin is generally well-tolerated; please refer to chemotherapy handouts for more information regarding chemotherapy side effects.

### **Radiation therapy:**

Is very effective at providing pain relief when surgical management is not an option. As few as two treatments are capable of complete or partial pain relief that typically lasts for several months. This treatment is non-painful and causes no immediate side effects other than hair loss in the therapy site. Typical survival times for dogs treated successfully with radiation therapy are 4-7 months. Quality of life during this time is generally very good and dogs can remain active and comfortable.

### **Pamidronate (bisphosphonate therapy):**

Is a medication that has been used in the past to treat osteoporosis, and is an anti-bone cancer drug that has been recently evaluated for treatment of canine osteosarcoma patients when amputation is not an option. Pamidronate has been most often combined with radiation therapy but several anecdotal reports exist for patients treated with only pamidronate that have had significant pain relief for several months. This drug is given IV once monthly for several months.

Prior to initiation of therapy, radiographs or a computed tomography (CT) scan of the chest cavity are recommended (for general health evaluation and cancer staging), along with a blood panel, urinalysis, and an abdominal ultrasound (for general health evaluation). A nuclear bone scan is available on-site (we are one of the few veterinary hospitals in Southern California that have this diagnostic procedure available in-hospital). The bone scan is used to identify other bone lesions in the body that may represent other sites of cancer. These bone lesions have been identified in up to 25% of dogs with osteosarcoma at the time of initial diagnosis. As an alternative, a whole body CT scan can provide a rapid and accurate means of evaluation of general health and for visible metastasis of osteosarcoma.

Osteosarcoma is a painful, aggressive disease. Your health care team at the Veterinary Specialty Hospital is equipped with the knowledge, procedures and compassion to assist you with decision-making and help your dog achieve a comfortable life and improved survival if diagnosed with this condition.